

# Feline Wound Management with Medicated Polyox Bandage

**SUMMARY:** Veterinary compounding plays a key role in the management of infected wounds. The polyox bandage is an innovative and versatile dosage form that facilitates topical application and wound healing by forming a durable, waterproof and occlusive layer. In this case study, an extensive leg wound in a cat was healed following 3 days of treatment with metronidazole 20% polyox bandage (PCCA Formula 4428).

Submitted by: Jocelyn Freimuth, R.Ph., ACA Compounding Pharmacy, Nashville (TN), USA.

## Introduction:

Feline patients commonly present infected skin wounds which must be treated promptly and effectively to prevent injury-related morbidity and mortality [1]. Veterinary compounding is an essential treatment option when the commercial medicines available do not fit the specific needs of animals. In wound management, the base of the formulation is a key component that determines the healing mechanism. A compounded polyox bandage is a powder wound-care base which may incorporate a variety of anti-infective agents, in combination with the anhydrous, free-flowing powder polyethylene oxide (Polyox WSR-301), to create a durable, waterproof, occlusive protective layer that facilitates healing of infected wounds [1,2].

## Case Report:

A stray cat was found bleeding from a large wound located on a back leg. The cause for the wound is unknown but the caregiver believes that the cat, named Ginger, had been bitten and escaped the attack. In order to prevent infection, a topical wound healing treatment was sought immediately. Metronidazole 20% Polyox Bandage (PCCA Formula 4428), as detailed in Table 1, was dispensed the next day by the local compounding pharmacy [3]. The caregivers were instructed to clean the wound with sterile water and then apply the bandage once daily to all affected areas.

Rx	
Metronidazole USP	2.5 g
Polyox® WSR-301	1 g
Methocel® E4M Premium	9 g

**Table 1.** Metronidazole 20% Polyox Bandage.

## Methodology:

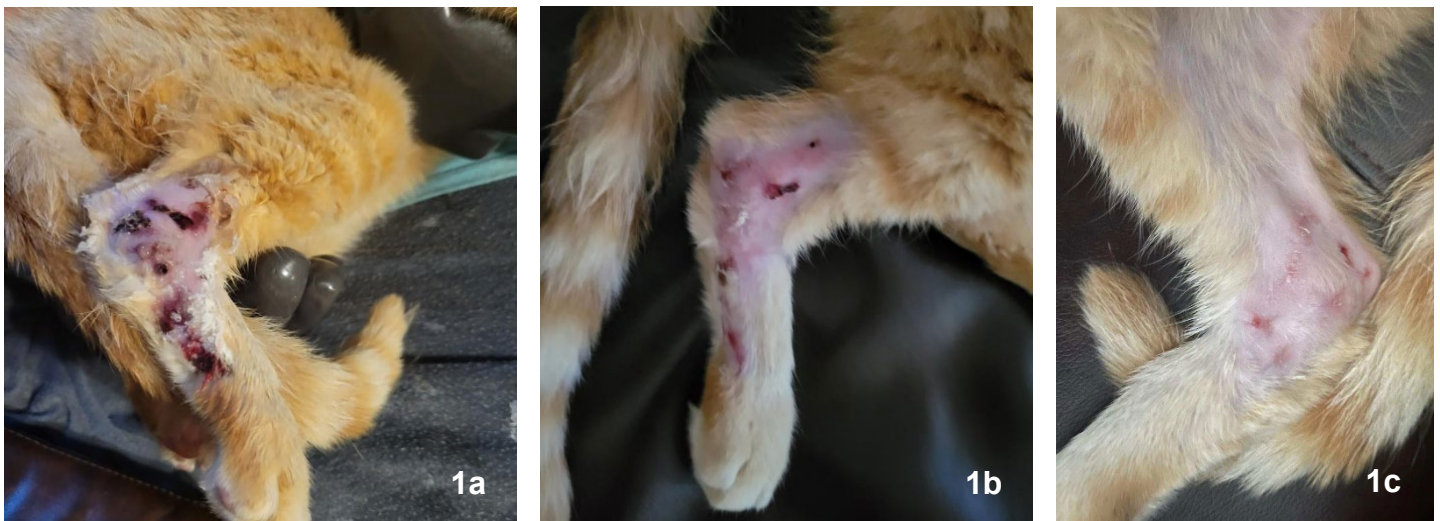
The research instrument used in this case study was a validated questionnaire that evaluates the quality of life of cats with skin disease and their owners, by Noli *et al.* It comprises 15 questions rated mainly as: not at all, a little, a fair amount, a lot. This instrument is sensitive to improvement following therapeutic interventions and it is therefore a great tool to evaluate the efficacy of the compounded medication [4]. Permission was requested and obtained to use it in this dermatology case study.

## Results and Discussion:

The caregiver completed the questionnaire retrospectively, with reference to before and after treatment with the medicated polyox bandage. Pictures of the leg wound were taken before treatment and 2-3 days after treatment (Figures 1a-1c).

Complete healing of the leg wound was achieved following 3 days of treatment only, as shown in Figure 1c. The before and after treatment questionnaire ratings showed a percentage of improvement of 92.9%. The caregiver and the compounded pharmacist were surprised with the efficacy of the compounded medication. The caregiver stated that the topical application of the medicated polyox bandage did not bother the cat (question 7 rated as 'not at all'). Applying medication to a wound is usually challenging because rubbing on a cream could disrupt the newly granulating tissue and it is a painful procedure. The innovative and versatile polyox bandage, on the other hand, is lightly dusted or puffed onto the wound, which facilitates the topical application. As this powder hydrates with the exudate, it adheres to the wound and forms a protective barrier [5]. Since it is an anhydrous powder, the estimated beyond-use date is extended to 6 months [6].

# Feline Wound Management with Medicated Polyox Bandage



**Figure 1a.** (left). Before treatment. **Figure 1b.** (middle). Post-treatment: Day 2. **Figure 1c.** (right). Post-treatment: Day 3.

## Testimonial

The medicated polyox bandage was great because it was anti-lick, waterproof, and healed the sore up without needing any additional care. The cat was healed up within 3 days!

The images and feedback have been fantastic and many of our local vets and zoo asked for this ultra-rapid healing pet bandage.

We would like to share our 'Happy Cat' story with PCCA and other pharmacies.



**Figure 1.** Photo of Ginger, a happy cat, 1 week after treatment.

## References:

1. Riepl M. Compounding Pearls, Wound Care: Base Selection. *Int J Pharm Compd.* 2020 Mar-Apr;24(2):98-102.
2. Allen V. Medicated Polyox Bandage for Skin Ulcers. *Int J Pharm Compd.* 2016 Mar-Apr;20(2):146.
3. Allen V. Metronidazole Benzoate 20 mg/g Polyox Bandage. *US Pharm.* 2015;40(4):45-46.
4. Noli C, Borio S, Varina A, Schievano C. Development and validation of a questionnaire to evaluate the Quality of Life of cats with skin disease and their owners, and its use in 185 cats with skin disease. *Vet Dermatol.* 2016 Aug;27(4):247-e58. doi: 10.1111/vde.12341.
5. Hover S. 3 Innovative Dosage Forms Standing The Test Of Time. PCCA Blog September 22, 2021. Available at: <https://www.pccarx.com/Blog/3-innovative-dosage-forms-standing-the-test-of-time>.
6. United States Pharmacopeial Convention. General chapter <795> pharmaceutical compounding—nonsterile preparations. USP 43–NF 38; 2020.